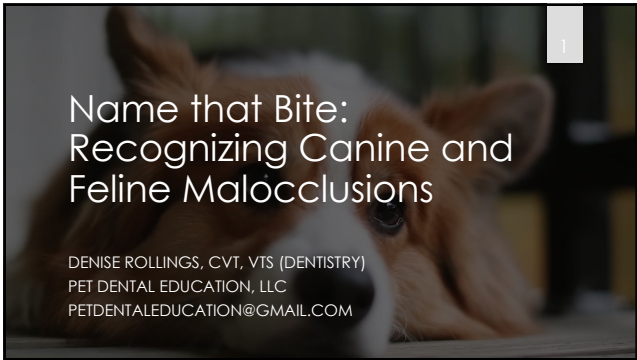



1

---

---

---

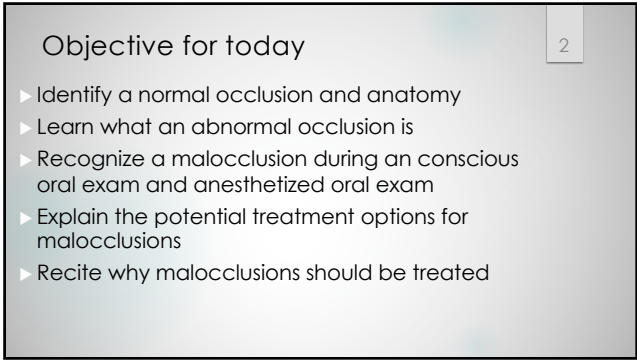
---

---

---

---

---



2

---

---

---

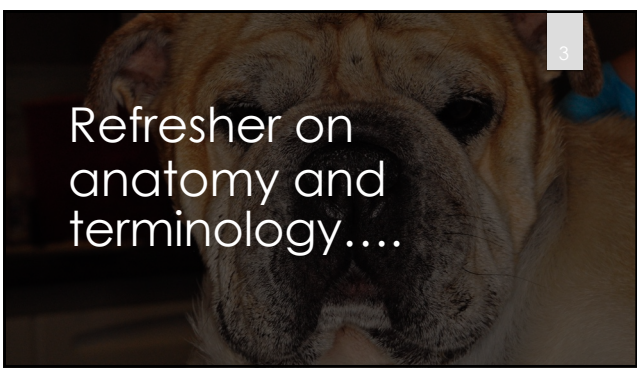
---

---

---

---

---



3

---

---

---

---

---


---

---

---

**Skull Anatomy**

- ▶ Maxilla:
- ▶ Right and left
- ▶ Grow independently
- ▶ Supports teeth of upper jaw
- ▶ Separates oral cavity from nasal cavity



4

---

---

---

---

---

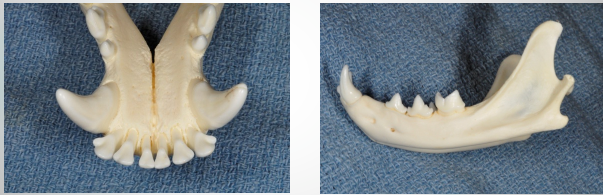
---

---

---

**Mandible**

- ▶ Supports the teeth of the lower jaw
- ▶ Right and left sides that meet in the middle at the symphysis (strong fibrous joint)



5

---

---

---

---

---

---

---

---



**Head Shape**  
Brachycephalic

6

---

---

---

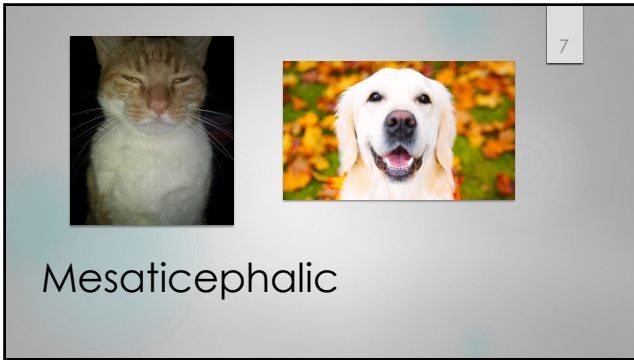---

---

---

---

---



7

---

---

---


---

---

---

---

---



8

---

---

---

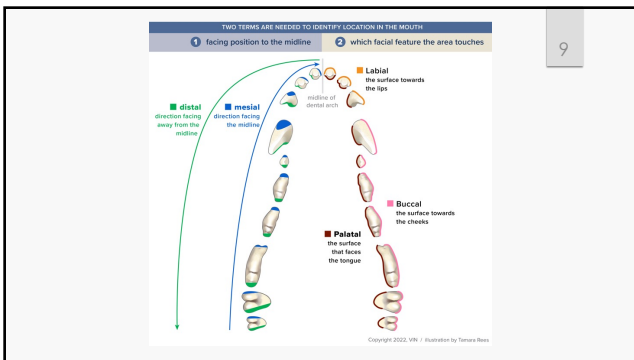
---

---

---

---

---



9

---

---

---

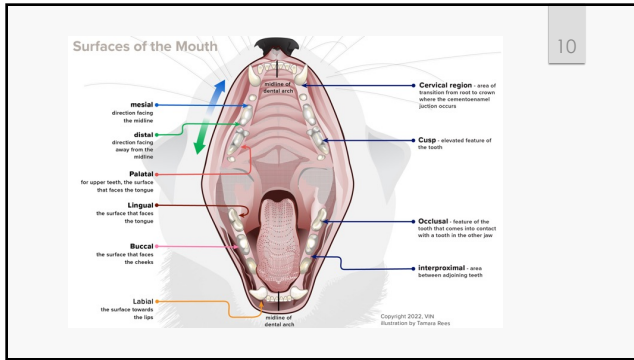
---

---

---

---

---



10

---

---

---

---

---

---

---

---

**Occlusion**

- ▶ The relationship of the maxillary and mandibular teeth when the mouth is closed or during movement of the mandible
- ▶ The teeth of the maxillary arch come into contact with the mandibular arch

**Occluding:** contacting opposing teeth

**Occlusal:** the biting surface of the tooth

11

---

---

---


---

---

---

---

---



Normal occlusion for canines and felines

12

---

---

---

---

---

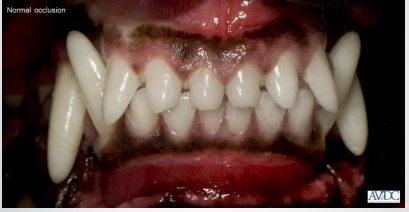---

---

---

The maxillary incisors overlap buccal (or labial) to the mandibular incisors

13



13

---

---

---

---

---

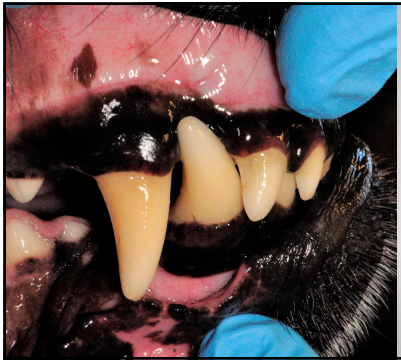---

---

---

The mandibular canine sits between the maxillary third incisor and the maxillary canine.

14



14

---

---

---

---

---

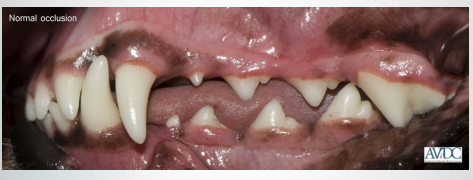---

---

---

The maxillary and mandibular premolars interdigitate in a pinking scissor bite; the maxillary fourth premolars sits buccal to the mandibular molar

15



15

---

---

---

---

---

---

---

---

### Malocclusion

16

- ▶ Any deviation from the normal occlusion
- ▶ May be genetic
- ▶ May be nongenetic
- ▶ No sex predilection
- ▶ May be classified pertaining to the teeth, jaw position, or both
- ▶ Categorized by Classes and subclasses

---

---

---

---

---

---

---

---

16

### Genetic vs. nongenetic

17

- ▶ Generally, jaw length malocclusions are considered genetic
- ▶ Generally, tooth discrepancies are nongenetic with the exception of lance canines in Persians and Shelties
- ▶ Factors include: trauma
  - late deciduous tooth loss
  - early deciduous tooth loss
  - dentigerous cysts
  - teeth grinding (bruxism)
  - abnormal or aggressive chewing behavior
  - nutritional

---

---

---

---

---

---

---

---

17

### Why do we treat malocclusions?

18

- ▶ Every patient has the right to comfortable bite!!!
- ▶ Generally, not treated for cosmetic reasons or for showing
- ▶ Need to discuss ethics with breeder




---

---

---

---


---

---

---

---

18



19

What do we look for?

- ▶ Jaws out of alignment
- ▶ Teeth out of alignment
- ▶ Oral trauma
- ▶ Bleeding
- ▶ Oral pain
- ▶ Periodontal disease
- ▶ Pulpitis
- ▶ Oral nasal fistula

---

---

---

---

---

---

---

---

19

Class 1 malocclusion  
MAL1:  
neutroclusion; jaws  
are in normal relation  
to each other with  
one or a few teeth  
out of place



20

---

---

---

---


---

---

---

---

20



21

MAL1/BV:  
  
Buccoversion – a  
tooth (or teeth)  
displaced in a  
buccal (or  
cheek) direction

---

---

---

---

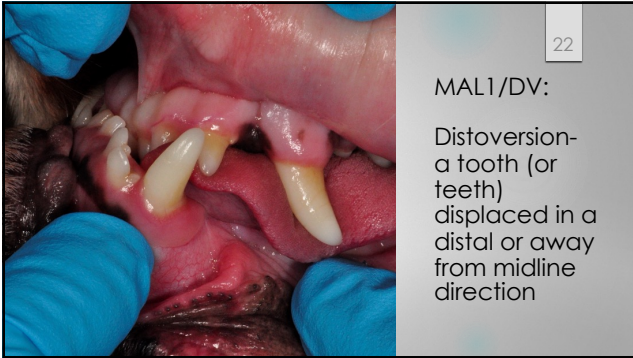---

---

---

---

21



22

MAL1/DV:

Distoverision-  
a tooth (or  
teeth)  
displaced in a  
distal or away  
from midline  
direction

---

---

---

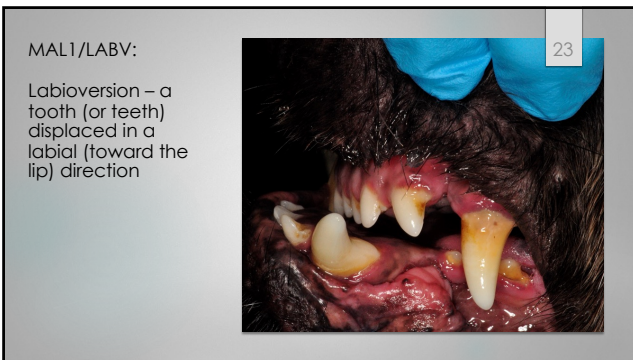---

---

---

---

22



23

MAL1/LABV:

Labioversion – a  
tooth (or teeth)  
displaced in a  
labial (toward the  
lip) direction

---

---

---

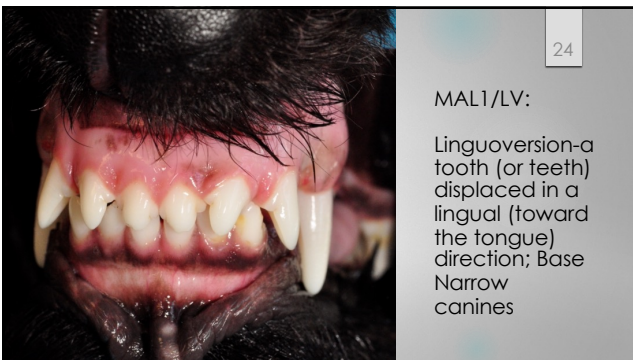---

---

---

---

23



24

MAL1/LV:

Linguoversion-a  
tooth (or teeth)  
displaced in a  
lingual (toward  
the tongue)  
direction; Base  
Narrow  
canines

---

---

---

---

---

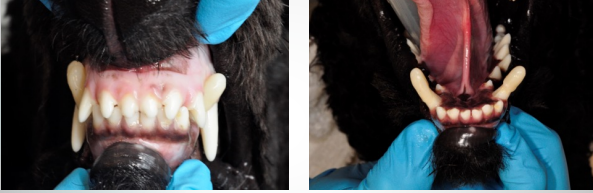
---

---

24

Crown lengthening/extensions

25



25

---

---

---

---

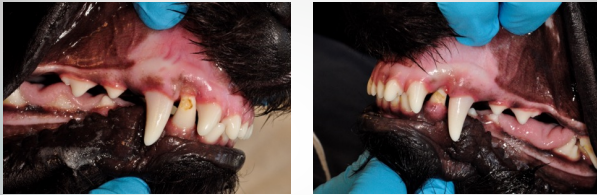---

---

---

---

26



26

---

---

---

---

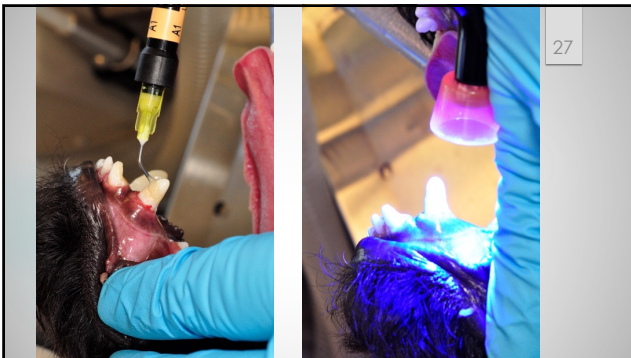---

---

---

---

27



27

---

---

---

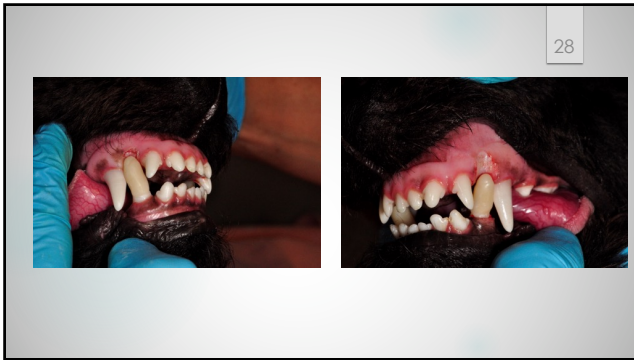---

---

---

---

---



28

---

---

---

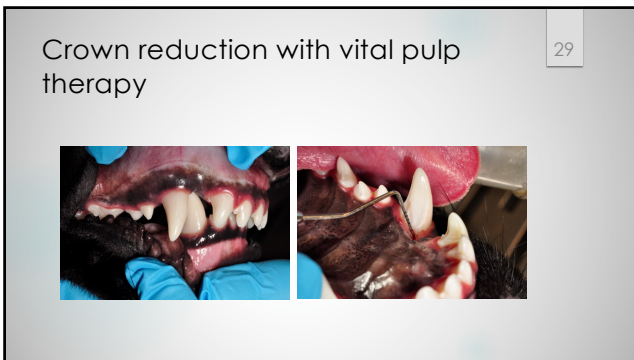
---

---

---

---

---



29

---

---

---

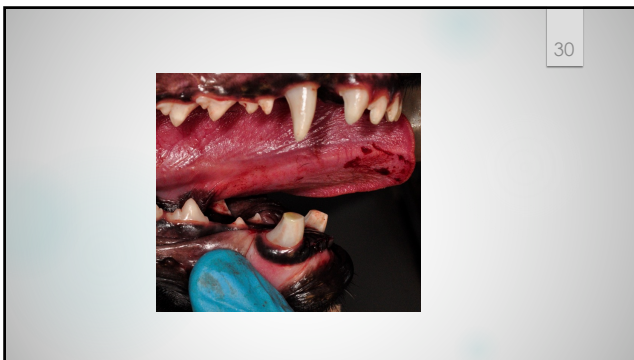
---

---

---

---

---



30

---

---

---

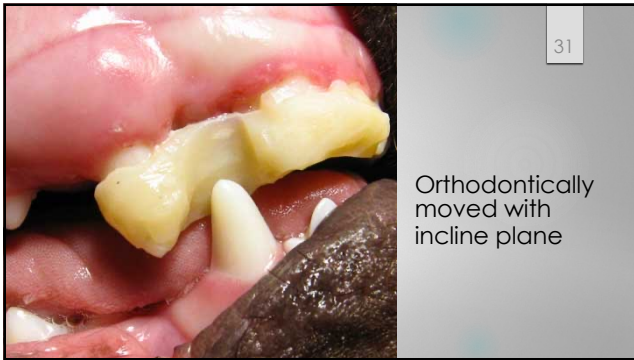---

---

---

---

---



31

---

---

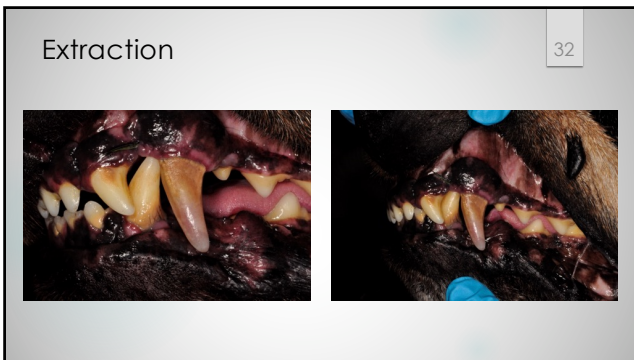
---

---

---

---

---



32

---

---

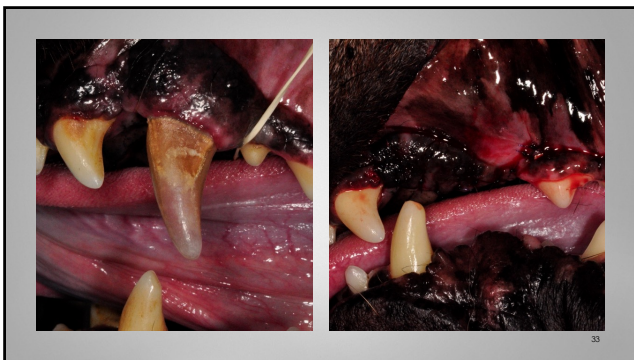---

---

---

---

---



33

---

---

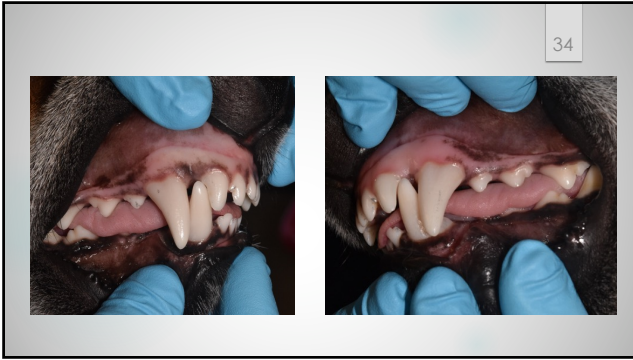
---

---

---

---

---



34

---

---

---

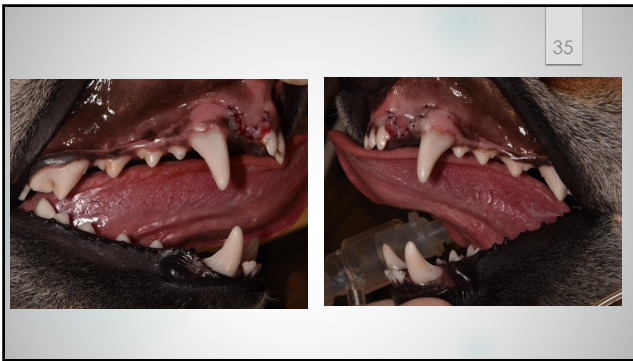---

---

---

---

---



35

---

---

---

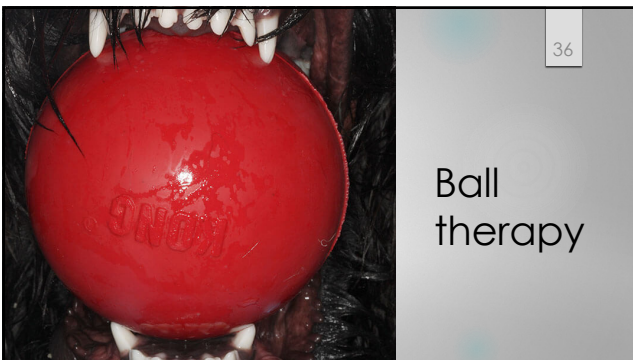---

---

---

---

---



36

---

---

---

---

---

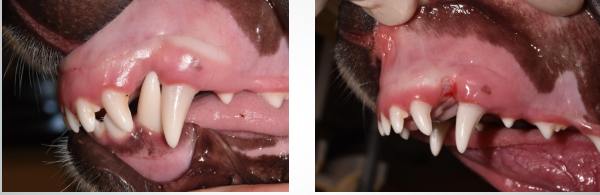---

---

---

Gingivoplasty

37



37

---

---

---

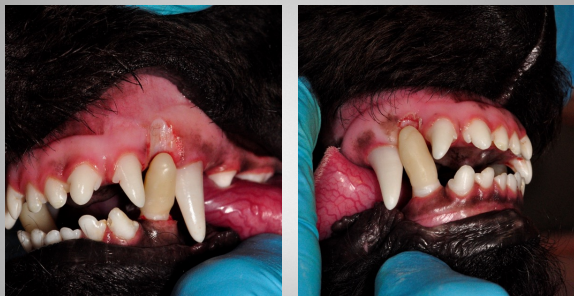---

---

---

---

---



38

---

---

---

---

---

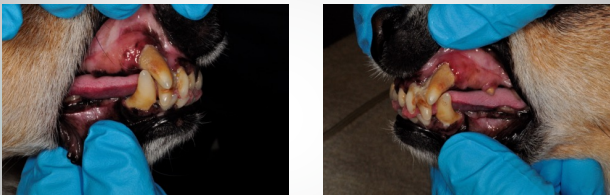
---

---

---

MAL1/MV: Mesioversion- a tooth (or teeth) displaced in a mesio (toward the midline) direction

39



39

---

---

---

---

---

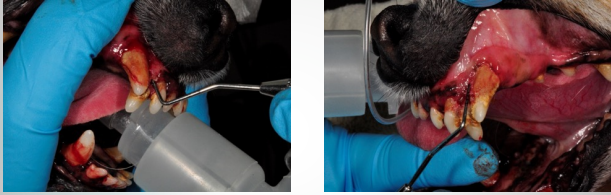---

---

---

### Lance canine

40



40

---

---

---

---

---

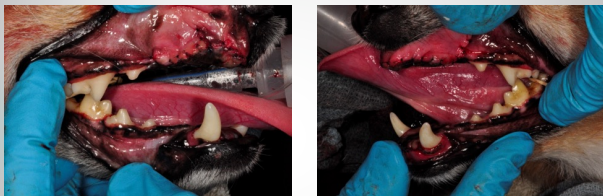
---

---

---

### Extraction

41



41

---

---

---

---

---

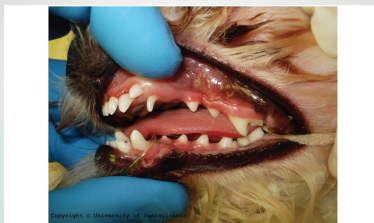---

---

---

### Orthodontic movement

42



Small Animal Dental Procedures for Veterinary Technicians and Nurses, 1st Edition, Edited by Jeanne R. Perrone, ©2013 John Wiley & Sons, Inc. Published 2013 by John Wiley & Sons, Inc.



Figure 7.13W An 18-month-old terrier mix dog presented for treatment for his malocclusion of the maxillary canine tooth and persistent deciduous tooth (C) 2010. Alexander M. Reiter, University of Pennsylvania

42

---

---

---

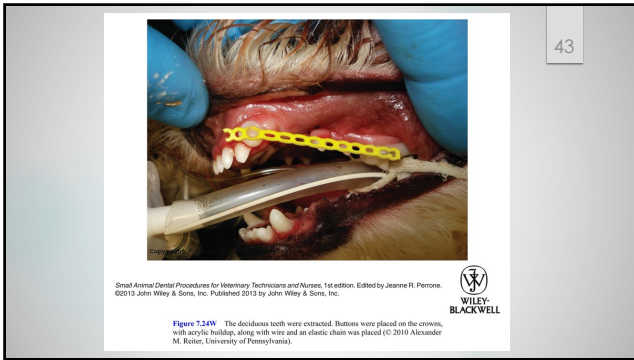---

---

---

---

---



43

---

---

---

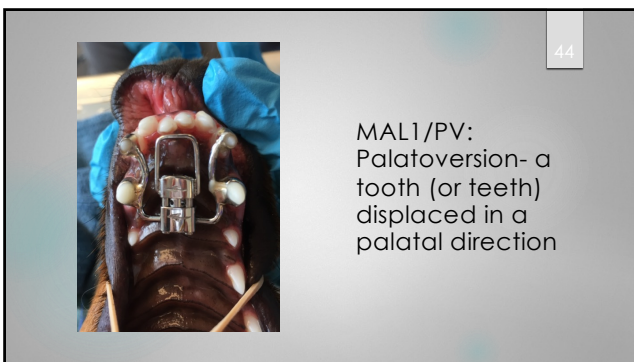
---

---

---

---

---



44

---

---

---

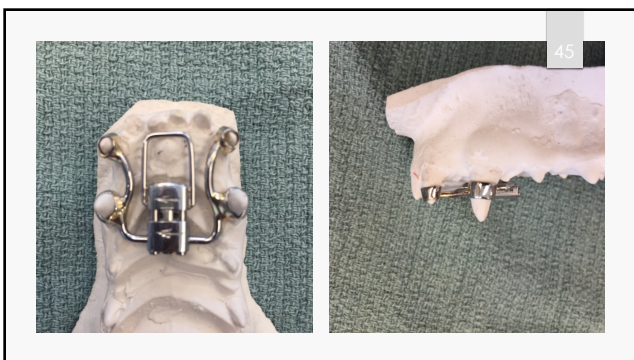
---

---

---

---

---



45

---

---

---

---

---

---

---

---

46

CB: Crossbite- one or more teeth are displaced in a buccal or labial direction



A frontal view of a dog's mouth showing a crossbite. The upper teeth are noticeably shifted towards the buccal (inner) side compared to the lower teeth.

---

---

---

---

---


---

---

46

47

CB/C: Caudal Crossbite- one or more mandibular premolars or molars is displaced in a buccal direction sitting buccal to the maxillary tooth



Two side-by-side photographs of a dog's mouth. The left image shows the upper teeth, and the right image shows the lower teeth. In both, the teeth are shifted towards the buccal side, illustrating caudal crossbite.

---

---

---

---

---

---

---

47

48



A close-up side view of a dog's teeth showing a crossbite. The teeth are shifted towards the buccal side.

---

---

---

---

---

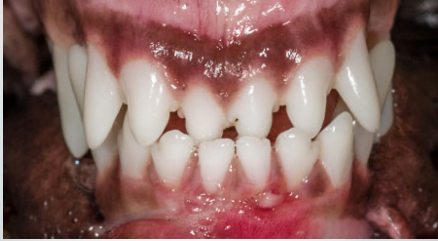---

---

48

CB/R: Rostral crossbite- one or more of the mandibular incisors is displaced labially sitting labial to the maxillary incisors

49



49

---

---

---

---

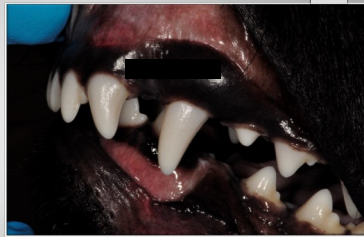---

---

---

Class 2 Malocclusion MAL2: the lower jaw is short in relation to the upper jaw (mandibular distocclusion)

50



50

---

---

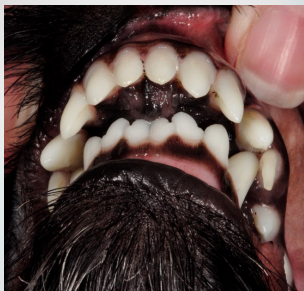---

---

---

---

---



51

51

---

---

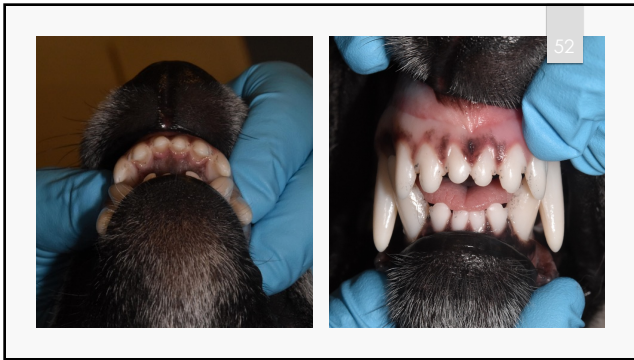---

---

---

---

---



52

---

---

---

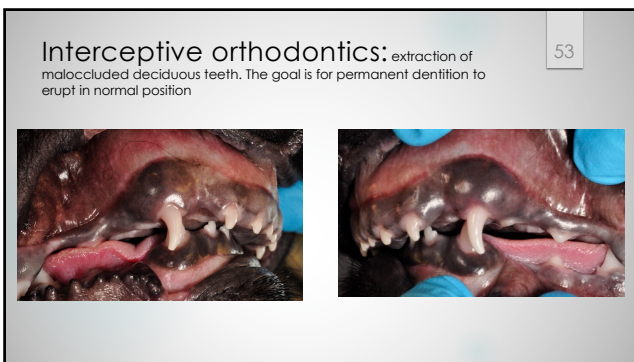---

---

---

---

---



53

---

---

---

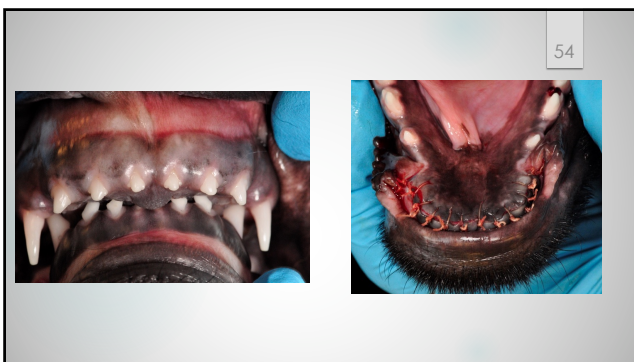
---

---

---

---

---



54

---

---

---

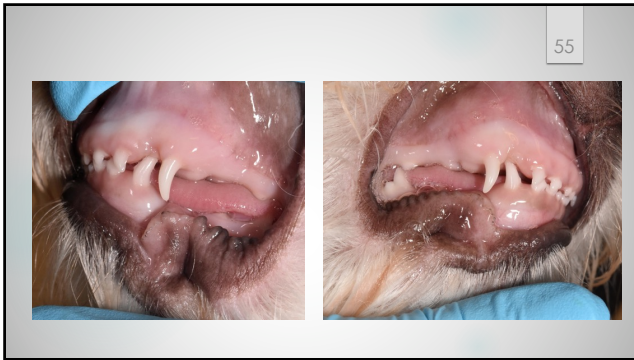---

---

---

---

---



55

---

---

---

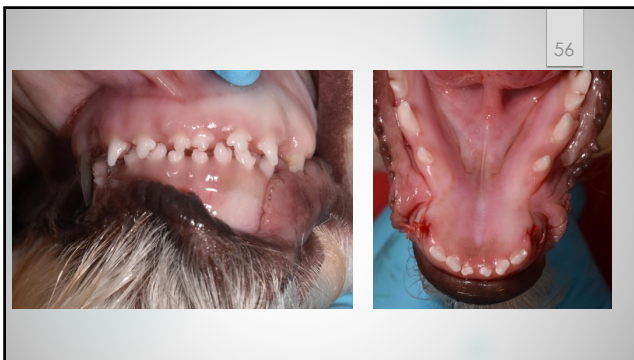---

---

---

---

---



56

---

---

---

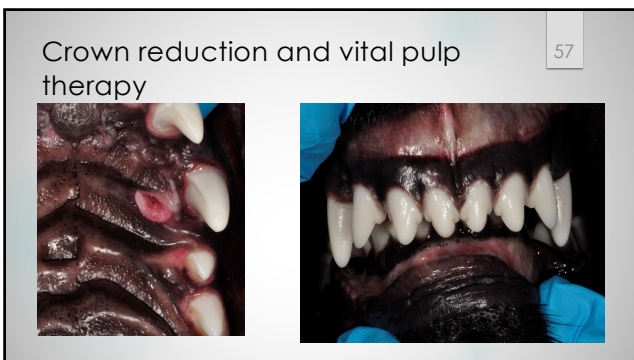
---

---

---

---

---



57

---

---

---

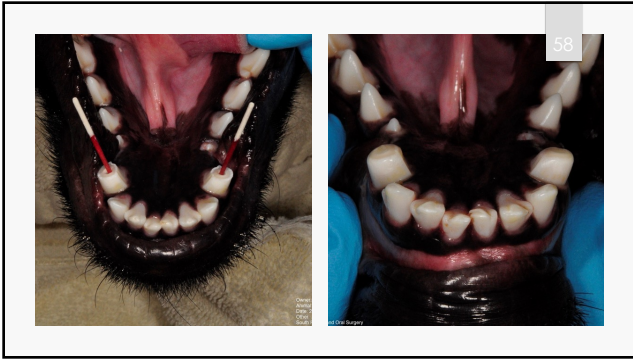---

---

---

---

---



58

---

---

---

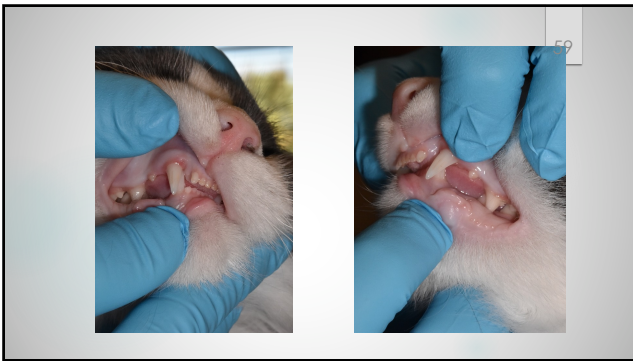---

---

---

---

---



59

---

---

---

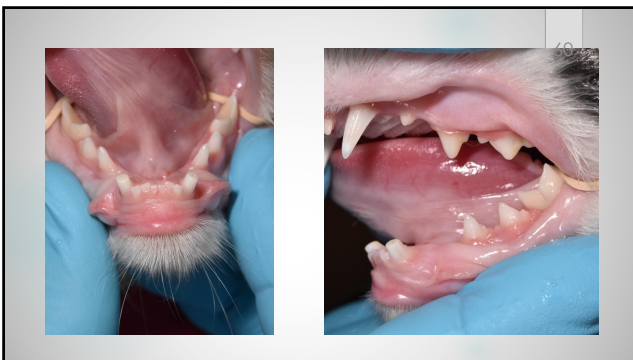---

---

---

---

---



60

---

---

---

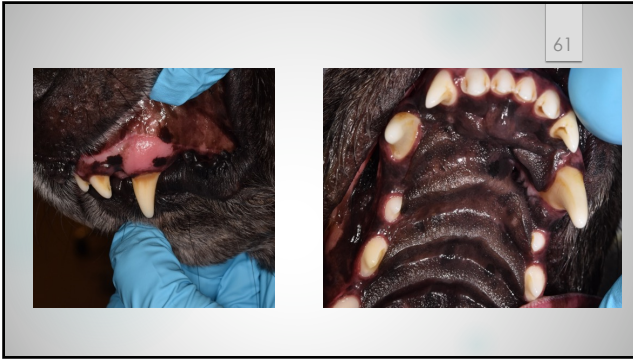---

---

---

---

---



61

---

---

---

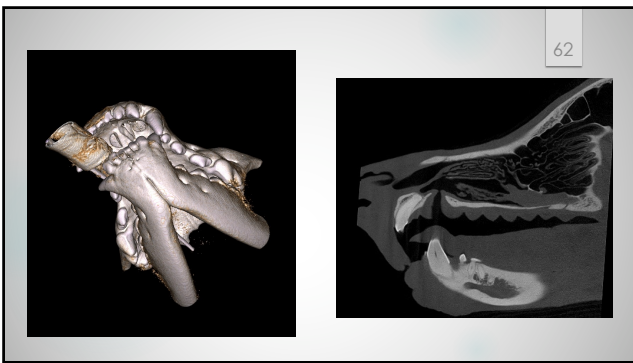
---

---

---

---

---



62

---

---

---

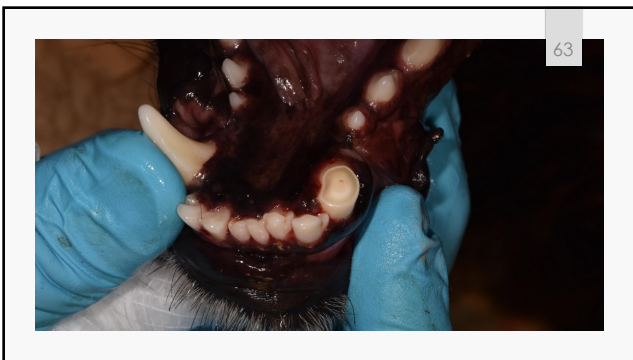---

---

---

---

---



63

---

---

---

---

---

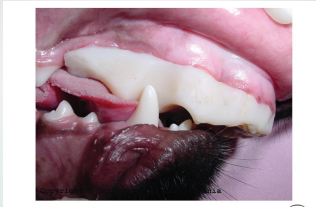---

---

---

# Orthodontic movement

64



Small Animal Dental Procedures for Veterinary Technicians and Nurses, 1st edition. Edited by Jeanne R. Perrone. ©2013 John Wiley & Sons, Inc. Published 2013 by John Wiley & Sons, Inc. WILEY-BLACKWELL  
Figure 1.29W An ortho bonded plate was placed on her incisors. Note the area of gingival recession in place for use of movement of the mandibular canine tooth (© 2010 Alexander M. Keller, University of Pennsylvania).

---

---

---

---

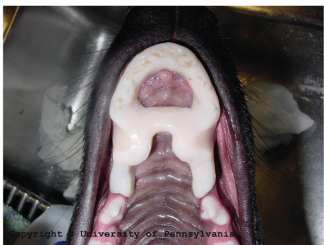---

---

---

---

64



65

Small Animal Dental Procedures for Veterinary Technicians and Nurses, 1st edition. Edited by Jeanne R. Perrone. ©2013 John Wiley & Sons, Inc. Published 2013 by John Wiley & Sons, Inc. WILEY-BLACKWELL  
Figure 1.30W Placement of the inclined plane on the palate (© 2010 Alexander M. Keller, University of Pennsylvania).

---

---

---

---

---

---

---

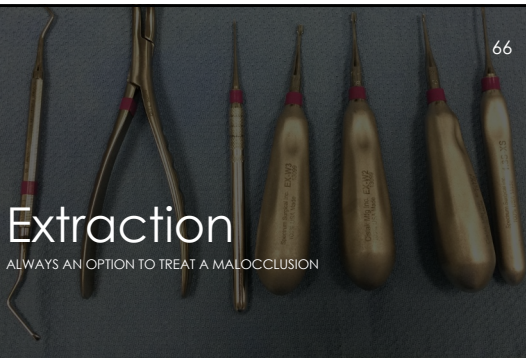
---

65

# Extraction

ALWAYS AN OPTION TO TREAT A MALOCCLUSION

66



---

---

---

---

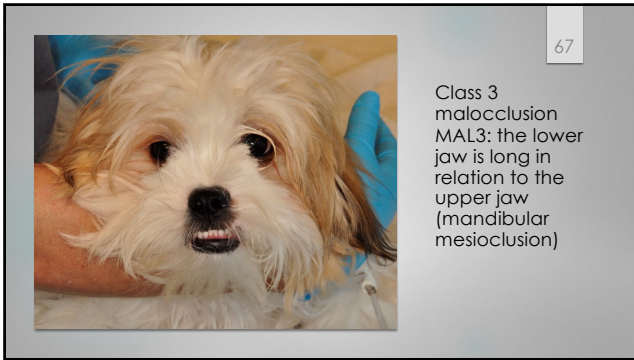---

---

---

---

66



67

Class 3 malocclusion  
MAL3: the lower jaw is long in relation to the upper jaw (mandibular mesioclusion)

---

---

---

---

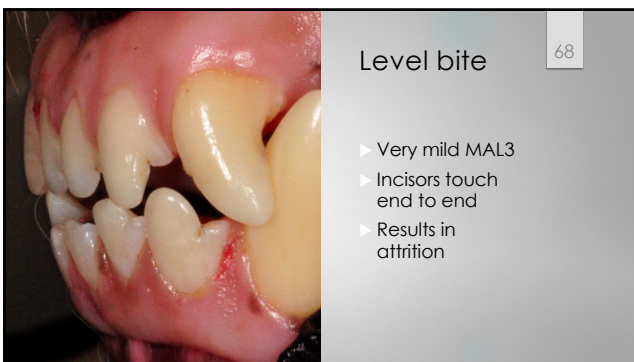
---

---

---

---

67



68

Level bite

- ▶ Very mild MAL3
- ▶ Incisors touch end to end
- ▶ Results in attrition

---

---

---

---

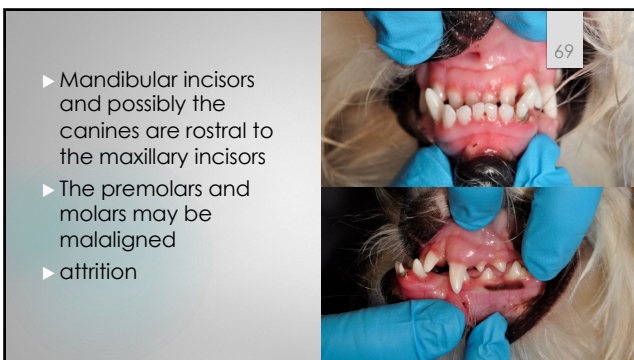
---

---

---

---

68



69

- ▶ Mandibular incisors and possibly the canines are rostral to the maxillary incisors
- ▶ The premolars and molars may be malaligned
- ▶ attrition

---

---

---

---

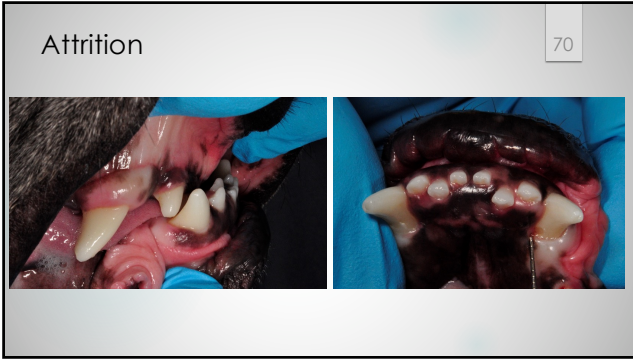
---

---

---

---

69



70

---

---

---

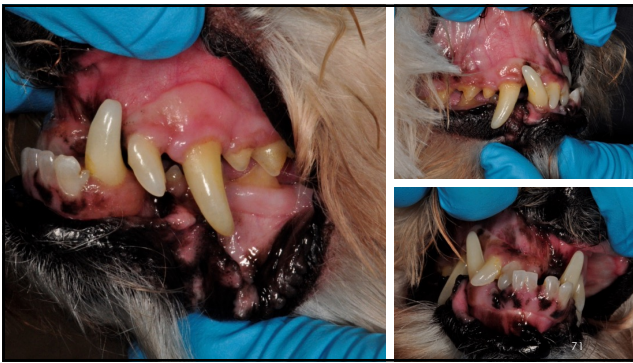---

---

---

---

---



71

---

---

---

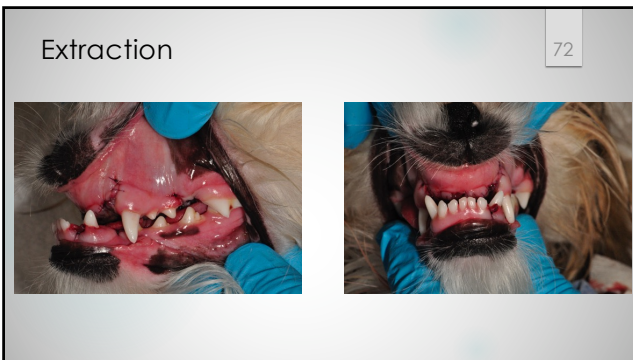
---

---

---

---

---



72

---

---

---

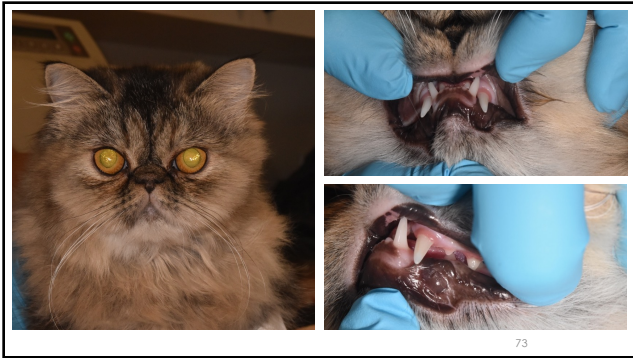---

---

---

---

---



73

---

---

---

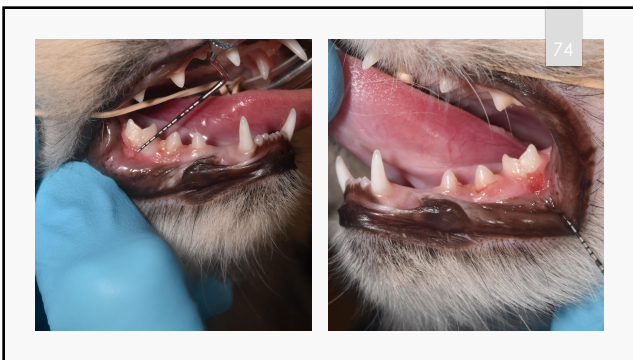---

---

---

---

---



74

---

---

---

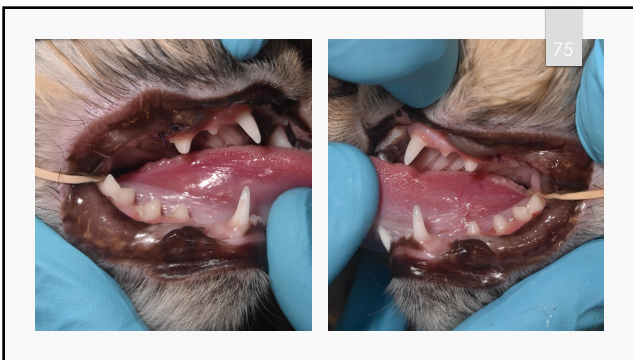
---

---

---

---

---



75

---

---

---

---

---

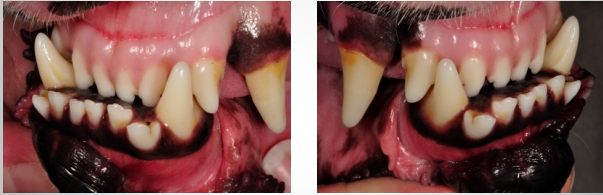
---

---

---

Odontoplasty and dentin bonding

76



76

---

---

---

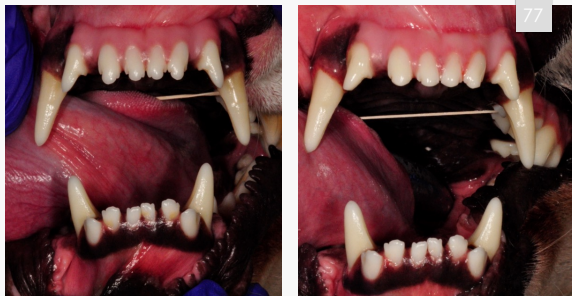---

---

---

---

---



77

77

---

---

---

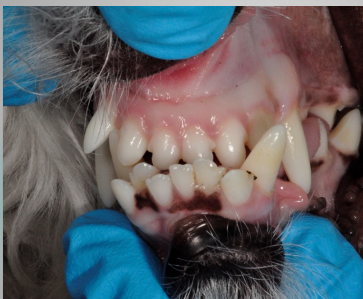---

---

---

---

---



78

Class 4 malocclusion  
MAL4:  
skeletal asymmetry in  
a caudoventral, left  
to right (side to side),  
or dorsoventral  
direction

78

---

---

---

---

---

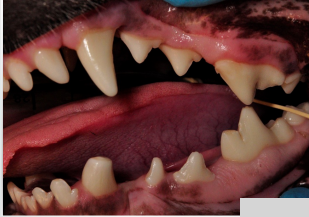---

---

---

MAL4/DV: skeletal asymmetry in a dorsoventral direction- there is an open bite creating an abnormal space between the maxilla and mandible

79



79

---

---

---

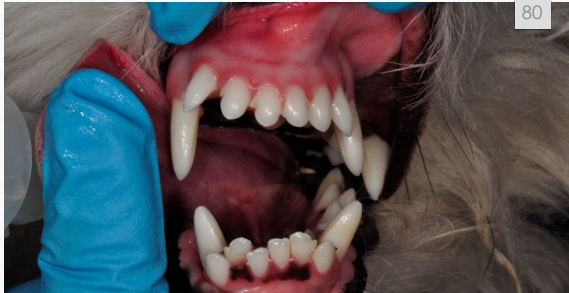---

---

---

---

---



80

80

---

---

---

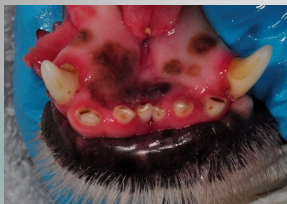---

---

---

---

---



MAL4/RC: skeletal asymmetry in a rostro caudal direction- the maxilla and mandible in normal relation on one side and either too short or too long on the opposite side

81

81

---

---

---

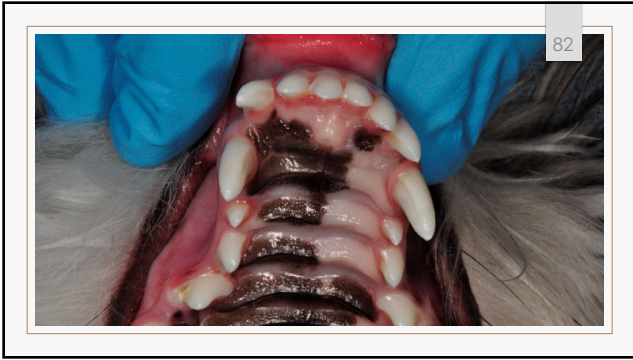---

---

---

---

---



82

---

---

---

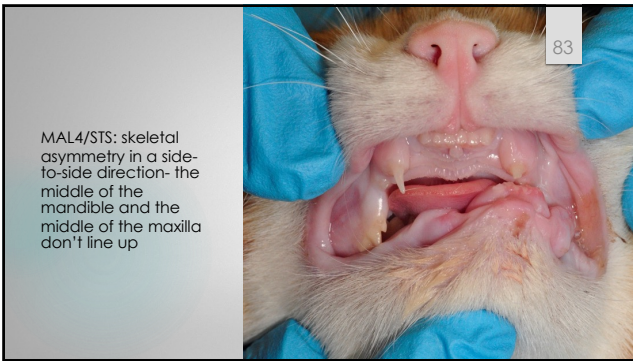---

---

---

---

---



83

---

---

---

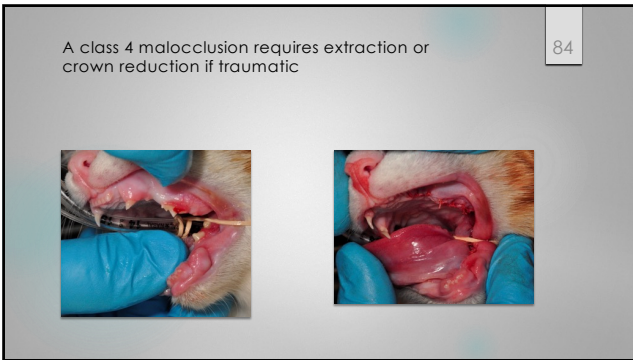
---

---

---

---

---



84

---

---

---

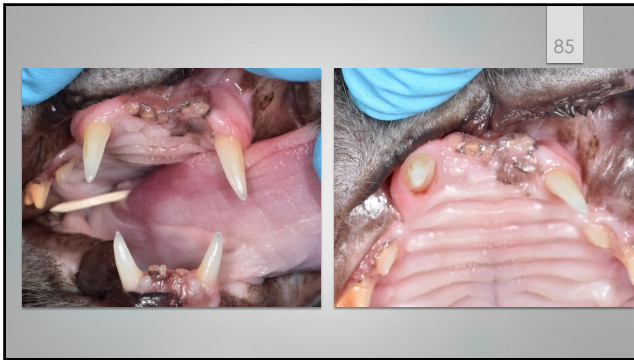---

---

---

---

---



85

---

---

---

---

---

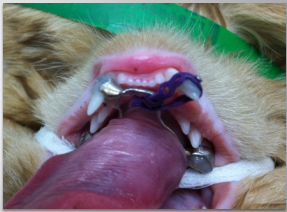
---

---

---

Every patient has a right to a comfortable bite!  
 What do we do to treat the malocclusion?

The treatment for any malocclusion causing trauma is extraction, crown reduction +/- vital pulp therapy, or orthodontic movement.



86

---

---

---

---

---

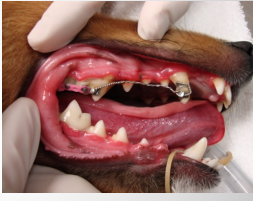
---

---

---

### Considerations

- ▶ Owners dedication
- ▶ Ability to provide home care
- ▶ Multiple anesthetic procedures
- ▶ Annual radiographs
- ▶ Patients health status and age
- ▶ Finances



87

---

---

---

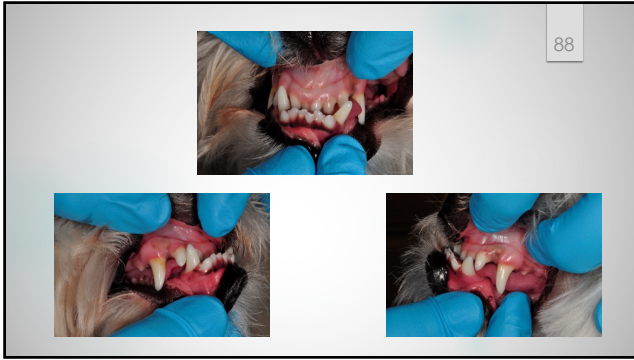---

---

---

---

---



88

---

---

---

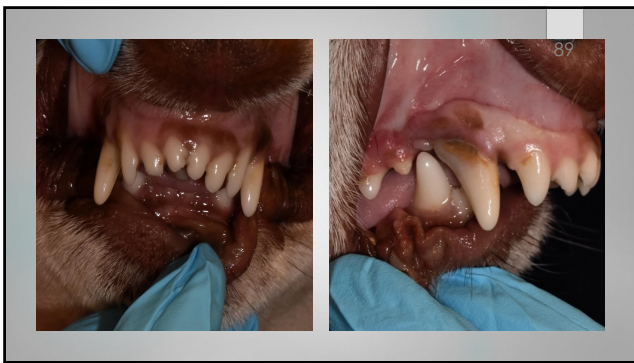---

---

---

---

---



89

---

---

---

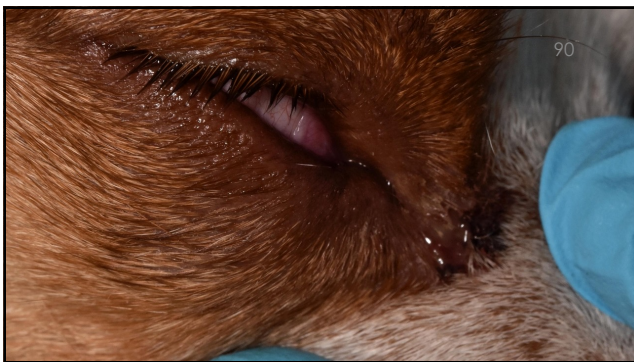---

---

---

---

---



90

---

---

---

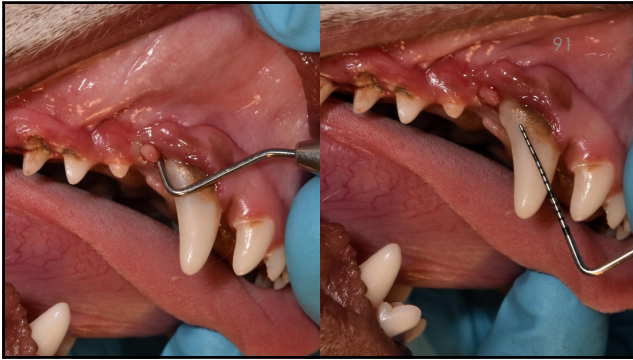---

---

---

---

---



91

---

---

---

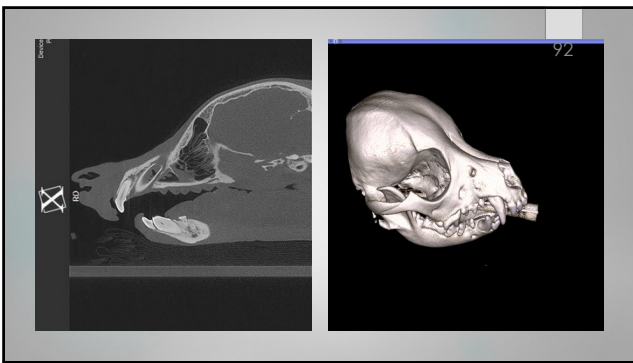
---

---

---

---

---



92

---

---

---

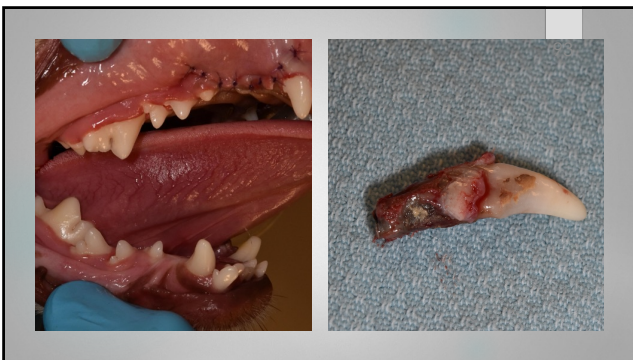---

---

---

---

---



93

---

---

---

---

---

---

---

---

94

**Thank You!**

For consulting, in clinic training, questions,  
comments, continuing education, resources:

Denise S. Rollings, AAS, CVT, VTS (Dentistry)  
Pet Dental Education, LLC  
[www.PetDentalEdu.com](http://www.PetDentalEdu.com)  
[PetDentalEducation@gmail.com](mailto:PetDentalEducation@gmail.com)



---

---

---

---

---

---

---