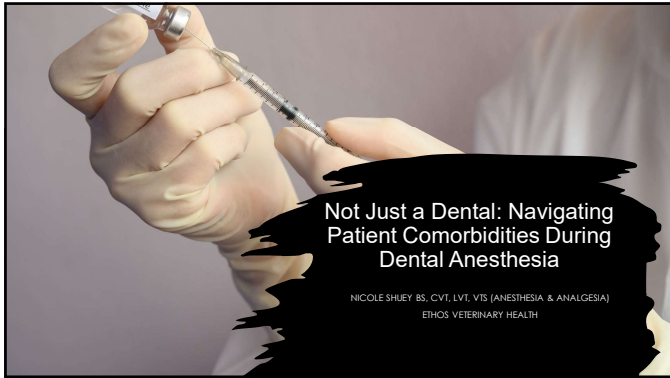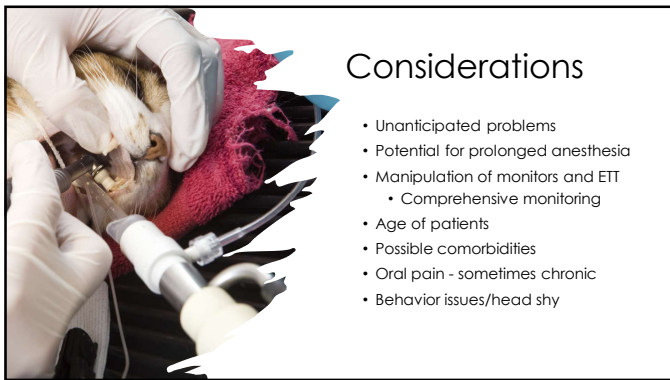
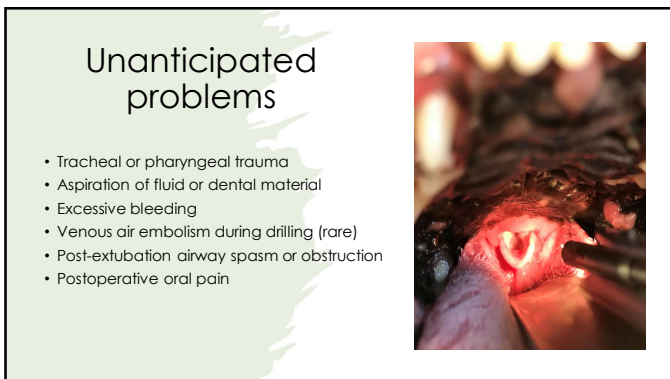


1



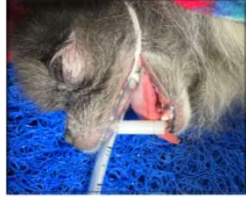2



3

Potential for Prolonged Anesthesia

- Increased risk of adverse events
 - Hypotension
 - Hypothermia
 - Hypoventilation
 - Prolonged recovery
- Exacerbation of underlying comorbidities
- Excessive pressure from mouth gags
- Eyes
 - Debris, drying, or decreased circulation from gag



4

Age of Patients



Increased risk of underlying comorbidities (+/- multiple)



More likely to have underlying dental pathology



Tracheomalacia potential

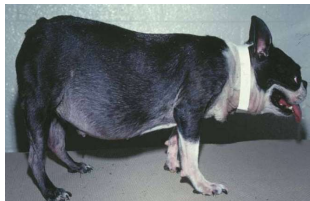

Delayed metabolism of drugs

5

Potential comorbidities

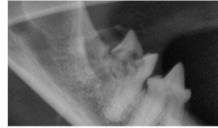
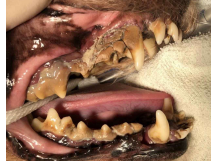- Cardiac
- Respiratory
- Renal
- Hepatic
- Endocrine
- Musculoskeletal



6

Oral Pain: Pre and Post

- Not every patient gets routine dental/oral hygiene
 - Cat owners
- "But he's been eating fine!"
- FORLs
- Stick/rawhide chewers
- Hyperalgesia



7

Pre-operative Preparation


- Preanesthetic fasting
- Pre-visit sedation
- Exam
- Bloodwork
- +/- thoracic radiographs
- Additional diagnostics



8

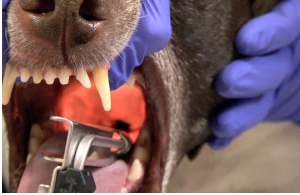Premedication

- Pain?
- Sedation
 - Pre-visits sent home?
 - Diagnostics
 - Catheter placement
 - Smooth induction
- Opioids
- Sedatives
- Benzodiazepines
- Dissociatives



9

Induction



- Preoxygenate!
- Injectables for rapid, smooth induction
 - Ketamine
 - Midazolam/diazepam
 - Propofol
 - Alfaxalone
 - Etomidate
- Multiple tubes available
- Preparation for difficult airway
- Wear gloves!

10


Maintenance

- All dental patients should be intubated
- IV fluid therapy
- Isoflurane or sevoflurane
- MAC reduction if needed
- Comprehensive monitoring
- Ventilation
 - Spontaneous
 - Manual
 - Mechanical



11

Comprehensive Monitoring



- Capnography/Capnometry
- Pulse Oximetry
- ECG
- Blood Pressure (direct or indirect)
- Temperature

12

Intraoperative Analgesia


- Local blocks
- Opioids
 - Full mu
 - Partial mu
- CRIs
- Ketamine
- NSAIDs



13

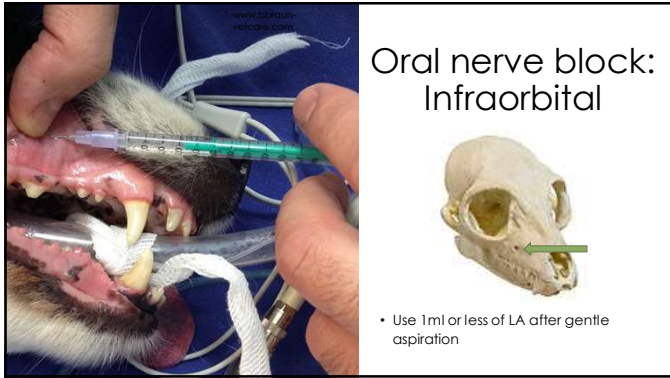
Oral nerve blocks

- Infraorbital
- Maxillary
- Mental
- Mandibular



14

Oral nerve block: Infraorbital

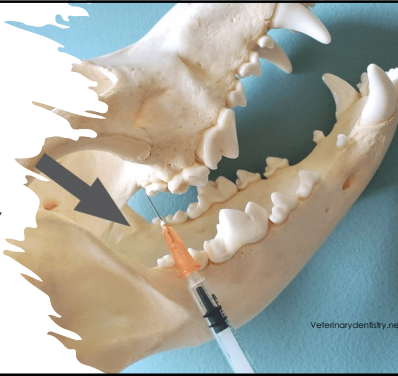


- Use 1ml or less of LA after gentle aspiration

15

Maxillary block

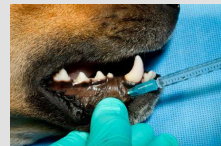
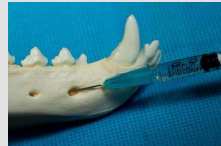- Oral approach:
 - Open mouth wide
 - Retract lips at lateral commissure
 - Insert 23-25g needle dorsally, immediately caudal to 2nd molar
 - Advance it 2-4 mm
 - Aspirate/inject LA



16

Mental block

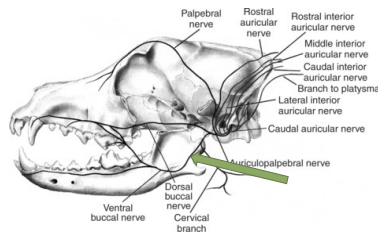
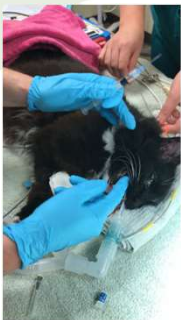- Location in dogs: Ventral to the 1st or 2nd premolar
- Location in cats: Half-way between the canine tooth and 3rd premolar
- Palpate the middle mental foramen
- Insert a small needle to the opening and advance it into the foramen
- Aspirate/inject LA



<https://internationalveterinarydentistryinstitute.org/rostral-mandibular-regional-block/>

17

Oral nerve block: Mandibular



18

Oral nerve blocks: Mandibular



- Intraorally, palpate mandibular nerve ventrally along vertical ramus of mandible
- Blocks incisors, canine, premolars, molars, and skin and mucosa of the chin and lower lip
- Caution to avoid loss of lingual sensation

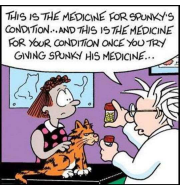
19

Recovery

- Clean out airway/mouth
- Remove any gauze
 - Create a reminder
- Extubation
 - Squeegee effect
 - Extra attention to cats if debris in nasal passages
- Evaluate pain
 - Re-dose analgesics as needed
- Address dysphoria



20



Post-operative analgesia

"Giving a cat a pill"

(Submit, beast)

What it feels like



What it looks like



(Minnie-Strap being such a fussy beast!)

- Level of pain
- Duration of blocks
- Oral vs. injectable
- Ease of administration
 - Owner compliance
 - Eating?
 - Mouth aversion?

21

Case Study: Bosco

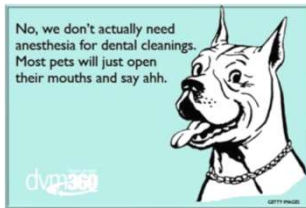
- 9yr M/N Pomeranian
- Cute but evil
- Halitosis, probably severe dental disease
 - No oral exam
 - Limited physical exam
 - Limited diagnostics
 - Overall healthy



22

Case Study: Bosco

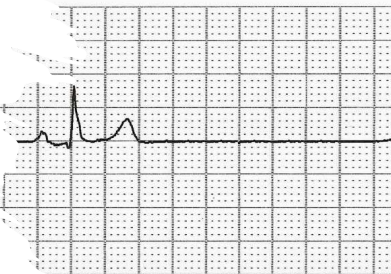- Pre-visit sedation
 - Gabapentin
 - Trazadone
- Still can't touch
 - High dose DKT
- Enough for catheter, BW (@induction)
- Induction with propofol



23

Case Study: Bosco

- Severe bradycardia under GA
- Mild hypotension
- Progresses to severe arrhythmias
 - Sinus pause, escape beats
 - Reverse dexdom after consideration
 - Not responding to anticholinergics
 - Decide to wake up/ try again another day
 - Chest rads not elected



24

Case Study: Bosco

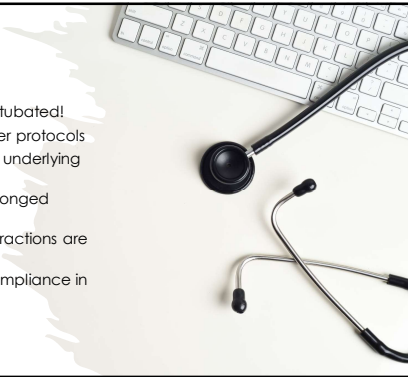- Change in pre-visit sedation
 - Chill protocol
 - No dexmed
- Torb/ketamine
- Prop induction, +/- ketamine top off
- Local blocks
- Anticholinergic once for bradycardia/mild hypotension
- Recovered AMAZING!



25

Key points


- Dental patients need to be intubated!
- Can't always use cookie cutter protocols
- Dental patients may still have underlying disease
- These patients may have prolonged anesthesia
- Need an analgesic plan if extractions are anticipated
- Keep recovery and owner compliance in mind



26

Questions?

nshueyts@gmail.com
 nicole.shuey@ethosvet.com



27
